



# MRI Shoulder Mini Fellowship

A Guided online course

## What's The Mini Fellowship About?

A Guided 30 day course where we cover the Imaging on MRI of intra and extra articular pathologies of the Shoulder. By the end of the Mini Fellowship you should be much more Confident to Assess and Report MRI of the Shoulder

## What Do We Cover?

All the relevant Anatomy, Pathology, Clinical and Imaging findings. Where to Look, What to Look For and How to Report them more Confidently.

## How Do You Learn It?

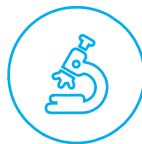Daily posts with a combination of text, images, videos, dicoms, quizzes and the ability to ask questions to Dr Ravi throughout the course to guide you and clear doubts.



Guided Learning



Anatomy



Pathology



Knowledge



Dicoms



Videos



Ask



Quiz



Badges



Certificate CME

## Who's Teaching



Dr Ravi, is the Director of Radiology Education Asia and a Senior Consultant Radiologist from Australia now in Singapore. He has been teaching MSK and Spine MRI for over 10 years and his aim in the courses is not just accumulating facts, but for you to be reporting more confidently at work.

His method of teaching is to simplify, without losing the essential things we need to know. For you to easily recognise the important anatomy, the relevant macroscopic pathology which helps to understand the imaging findings and for you to know where to look and what to look for. All of these help you to report a scan with Confidence and issue reports that you are proud of and will be respected by referrers.

*Report with Confidence*



# REPORT MORE CONFIDENTLY: TOPICS COVERED

## 1. SEQUENCES/ REPORTING STRUCTURE/ APPROACH TO ASSESSING A SCAN

## 2. NORMAL LABRUM VARIANTS

- Anatomy/ location
- Sublabral recess
- Sublabral foramen
- Buford complex
- Anatomy of the middle gleno humeral ligament
- Differentiation of variant vs tear

## 3. SHOULDER INSTABILITY

- Hills sachs
- Labral tear
- Periosteal stripping ighl tear
- Cartilage tear
- Bony bankart

## 4. HAGL & HAGL

- What are they and how to find

## 5. SLAP TEARS

- Main types
- Differentiation from normal variants

## 6. DENERVATION

- Suprascapular nerve (paralabral cysts)
- Parsonage turner

## 7. CAPSULITIS

- Ighl capsulitis
- Rotator interval capsulitis

## 8. SUBACROMIAL IMPINGEMENT

- Subacromial space
- OS acromiale

## 9. SUPRASPINATUS & INFRASPINATUS

- Anatomy and how to differentiate the tendons

## 10. TENDON DEGENERATION

- Fraying
- Tendonosis
- Delamination

## 11. TENDON TEARS


- Delaminating tears
- Partial tears
- Localised full thickness tears
- Complete full thickness tears

## 12. SUBSCAPULARIS

- Anatomy
- Tendonosis and tears

## 13. BICEPS TENDON

- Anatomy
- Tendonosis tears
- Subluxation
- Dislocation



Scan QR Code or Visit  
<https://bit.ly/mrshoulder>  
to register

 <https://www.facebook.com/RadEdAsia/>

 <https://www.youtube.com/c/radedasia>

 <https://www.linkedin.com/in/radedasia/>

 <https://radedasia.com/>

 <https://www.instagram.com/radedasia>

 <https://wa.me/6594882623>

 <https://twitter.com/RadEdAsia>

 <https://t.me/radiologyedasia>

## CPD FOR THE COURSE

30 CPD Hours for web-based learning by the Royal Australian and New Zealand College of Radiologists (RANZCR). RANZCR CPD/CME are recognised by most international licensing agencies. Please check with your licensing agency.



The Royal Australian  
and New Zealand  
College of Radiologists